

Research article

Open Access

## Peroxynitrite decomposition catalyst ameliorates renal damage and protein nitration in cisplatin-induced nephrotoxicity in rats

Yolanda I Chirino<sup>1</sup>, Rogelio Hernández-Pando<sup>2</sup> and José Pedraza-Chaverri\*<sup>1</sup>

Address: <sup>1</sup>Departamento de Biología, Facultad de Química, Edificio B, Segundo Piso, Lab 209, Ciudad Universitaria, UNAM, México D.F. México and <sup>2</sup>Departamento de Patología, Instituto Nacional de Ciencias Médicas y Nutrición "Salvador Zubirán" 14000, México, D.F. México

Email: Yolanda I Chirino - irasema\_chirino@hotmail.com; Rogelio Hernández-Pando - rhdezpando@hotmail.com; José Pedraza-Chaverri\* - pedraza@servidor.unam.mx

\* Corresponding author

Published: 30 September 2004

Received: 22 July 2004

BMC Pharmacology 2004, 4:20 doi:10.1186/1471-2210-4-20

Accepted: 30 September 2004

This article is available from: <http://www.biomedcentral.com/1471-2210/4/20>

© 2004 Chirino et al; licensee BioMed Central Ltd.

This is an open-access article distributed under the terms of the Creative Commons Attribution License (<http://creativecommons.org/licenses/by/2.0>), which permits unrestricted use, distribution, and reproduction in any medium, provided the original work is properly cited.

### Abstract

**Background:** Oxidative stress is involved in cisplatin-nephrotoxicity. However, it has not completely established if reactive nitrogen species and nitrosative stress are involved in this experimental model. The purpose of this work was to study the role of peroxynitrite, a reactive nitrogen specie, in cisplatin-nephrotoxicity using the compound 5,10,15,20-tetrakis (4-sulfonatophenyl) porphyrinato iron (III) (FeTPPS), a soluble complex able to metabolize peroxynitrite.

**Results:** In rats treated with cisplatin (a single intraperitoneal dose of 7.5 mg/kg body weight), renal nitrosative stress was made evident by the increase in 3-nitrotyrosine on day 3. In addition, cisplatin-induced nephrotoxicity was evident by the histological damage of proximal tubular cells and by the increase in (a) serum creatinine, (b) blood urea nitrogen, and (c) urinary excretion of N-acetyl-β-D-glucosaminidase and total protein. Cisplatin-induced nitrosative stress and nephrotoxicity were attenuated by FeTPPS-treatment (15 mg/kg body weight, intraperitoneally, every 12 hours for 3 days).

**Conclusions:** Nitrosative stress is involved in cisplatin-induced nephrotoxicity in rats. Our data suggest that peroxynitrite is involved, at least in part, in cisplatin-induced nephrotoxicity and protein nitration.

### Background

Cisplatin (cis-dichlorodiammine-platinum II) is an effective antineoplastic agent in the treatment of various solid tumours [1] including cancers of the ovary, testis, bladder, head, neck, lung, cervix, and endometrium [2]. Nevertheless, its full clinical utility is limited due to some adverse side effects including acute renal failure. The major site of renal injury is the S3 segment of the proximal tubule, located in the outer stripe of the outer medulla of the kidney [1]. The production of reactive oxygen species (ROS)

and oxidative stress in kidney have been implicated in the pathogenesis of cisplatin-induced renal injury [3]. It has been shown that superoxide anion ( $O_2^{\bullet-}$ ) [4], hydrogen peroxide ( $H_2O_2$ ) [5], and hydroxyl radical ( $\bullet OH$ ) [6] are involved in cisplatin-induced nephrotoxicity. In addition, it has been found that renal lipid peroxidation [5,7] is increased and glutathione is decreased [8] in this experimental model. The involvement of oxidative stress is further supported by the fact that the antioxidants melatonin [9] and vitamins C and E [5,10] prevent cisplatin-induced

nephrotoxicity. Interestingly, overexpression of heme oxygenase-1 ameliorates [11] and heme oxygenase-1 deficiency [12] aggravates renal damage induced by cisplatin, supporting additionally the involvement of oxidant stress in this experimental model.

On the other hand, the role of reactive nitrogen species (RNS) and nitrosative stress has been less explored in cisplatin-induced nephrotoxicity. In this context, it has been studied the role of nitric oxide ( $\text{*NO}$ ) and nitric oxide synthase (NOS) [13-19]. It has been found that the renal content of total nitrate/nitrite is increased in cisplatin-treated rats [18,19] suggesting that  $\text{*NO}$  production is enhanced in these animals. Furthermore, the inhibition of NOS by L-NAME [14] or by aminoguanidine [13] decreased renal damage induced by cisplatin, suggesting that  $\text{*NO}$  is playing a toxic role in this experimental model. However, it is unknown if peroxynitrite ( $\text{ONOO}^-$ ), a RNS that is generated by the reaction of  $\text{*NO}$  and  $\text{O}_2^{\bullet-}$ , is involved in the renal damage induced by cisplatin. It has been shown that  $\text{ONOO}^-$ , which is not a free radical, is involved in the pathogenesis of many diseases [20-25].  $\text{ONOO}^-$  can react with different biomolecules including amino acids such as cysteine, methionine, tryptophan, and tyrosine leading to changes in protein structure and function [26].  $\text{ONOO}^-$  has been shown to cause lipid peroxidation, chemical cleavage of DNA, and reduction in cellular defenses by oxidation of thiol pools [27].

In this work, we studied if  $\text{ONOO}^-$  is involved in the nephrotoxicity induced by cisplatin by using 5,10,15,20-tetrakis (4-sulfonatophenyl) porphyrinato iron (III) (FeTPPS). This compound is a water-soluble Fe (III) porphyrin complex that catalyzes rapid isomerization of  $\text{ONOO}^-$  to nitrate ( $\text{NO}_3^-$ ) under physiologically relevant conditions (pH 7.4, 37°C) [28]. The cytoprotective actions of FeTPPS have been characterized [29].

## Results

### Body weight and urinary volume

Body weight decreased 8.5% in cisplatin (Cis) group on day 3 and FeTPPS tended to prevent this decrease in Cis+FeTPPS group, however there was no significant difference between Cis and Cis+FeTPPS groups. Body weight was similar in control (Ct), FeTPPS, and Cis+FeTPPS groups. Urinary volume was not significant difference among the four groups along the study and on day of sacrifice (Table 1).

### Markers of glomerular and tubular damage

Serum creatinine increased 4.9 times and blood urea nitrogen (BUN) increased 5.5 times in Cis group compared to control one (Fig 1). FeTPPS prevented partially the increase in serum creatinine and BUN levels in Cis+FeTPPS group. Cisplatin increased urinary excretion

**Table 1: Body weight and urinary volume in the 4 groups of rats studied on day 3.**

	Ct	Cis	FeTPPS	Cis+ FeTPPS
Body weight (g)	235 ± 5 <sup>a</sup>	215 ± 4 <sup>b</sup>	238 ± 3 <sup>a</sup>	231 ± 4 <sup>a</sup>
Urinary volume (mL/24 h)	5.7 ± 1.4 <sup>a</sup>	7.4 ± 0.8 <sup>a</sup>	3.5 ± 1.1 <sup>a</sup>	7.4 ± 1.6 <sup>a</sup>

Values are mean ± SEM. n = 6. Groups with different letter are significantly different (P < 0.05).

of total protein (4.6 times) and N-acetyl- $\beta$ -D-glucosaminidase (NAG) (9.6 times) (Fig 2A and 2B). The increase in both parameters was prevented by FeTPPS in Cis+FeTPPS group (Fig 2). Serum creatinine, BUN, and urinary excretion of total protein and NAG were similar in Ct and FeTPPS groups (Figs 1 and 2).

### Histological analysis

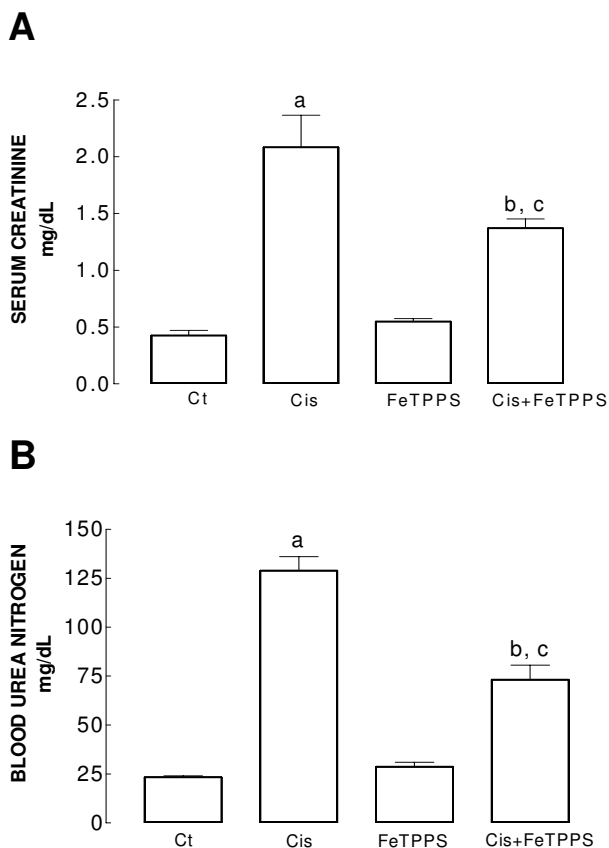
After three days of cisplatin-treatment, the epithelium from proximal convoluted tubules (tubules with small lumen area and taller epithelial cells) showed cytoplasmic vacuolization, intracellular edema and extensive damage which affected 87 ± 4% of their surface area (Fig 3B). The cisplatin toxic activity was higher in the straight portion of proximal convoluted tubules located in the inner area of the kidney cortex, where more than 90% of the epithelial surface suffered damage (Fig 4B). Interestingly, FeTPPS administration partially decreased the damaged area from 87 ± 4 to 44 ± 6% (p < 0.0001) in proximal convoluted tubules (Fig 3D) and from 93 ± 2 to 68 ± 10 (p < 0.0001) in the straight portion (Fig 4D). The administration of FeTPPS did not produce any histological alteration in the kidneys (Figs 3C and 4C). At the light microscopy level, glomeruli structure remained unchanged in all groups.

### Immunohistochemical localization of 3-nitro-L-tyrosine (3-NT)

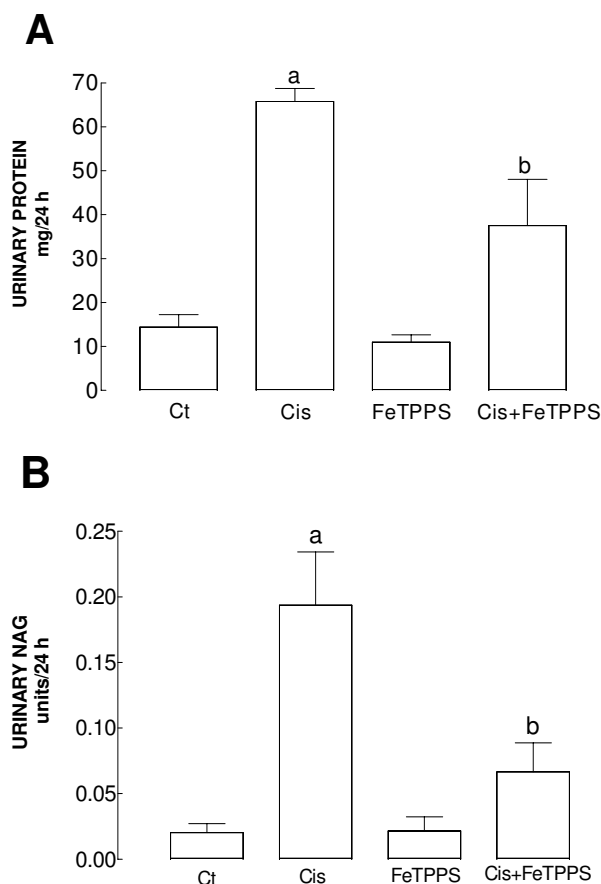
A strong 3-NT immunostaining was observed in the straight portion of the proximal convoluted tubules located in the inner area of the kidney cortex of cisplatin-treated rats (Fig 5B). Interestingly, in the Cis+FeTPPS group, FeTPPS administration partially prevented the cisplatin toxic damage in the epithelium from the proximal convoluted tubules and its straight portion respectively, in coexistence with an evident decrease of 3-NT immunostaining (Fig 5D).

## Discussion

Cisplatin in an effective chemotherapeutic agent for a wide variety of tumors, nevertheless, nephrotoxicity is the major complication of this antineoplastic treatment [1]. The mechanism by which cisplatin causes renal damage is unclear, however, it has been postulated that oxidative



**Figure 1**  
 (A) Serum creatinine and (B) BUN on day 3 in the four groups of rats studied. Ct: control group, Cis: cisplatin group; FeTPPS: 5,10,15,20-tetrakis(4-sulfonatophenyl) porphyrinato iron (III) group, and Cis+FeTPPS: cisplatin+5,10,15,20-tetrakis(4'-sulfonatophenyl) porphyrinato iron (III) group. Data are mean ± SEM. n = 6. <sup>a</sup>P < 0.001 vs. Ct; <sup>b</sup>P < 0.001 vs. Ct, <sup>c</sup>P < 0.05 vs Cis (Panel A); <sup>a</sup>P < 0.001 vs. Ct; <sup>b</sup>P < 0.001 vs. Ct, <sup>c</sup>P < 0.001 vs Cis (Panel B). Serum creatinine and BUN increased in cisplatin group and FeTPPS prevented these increases in the Cis+FeTPPS group.

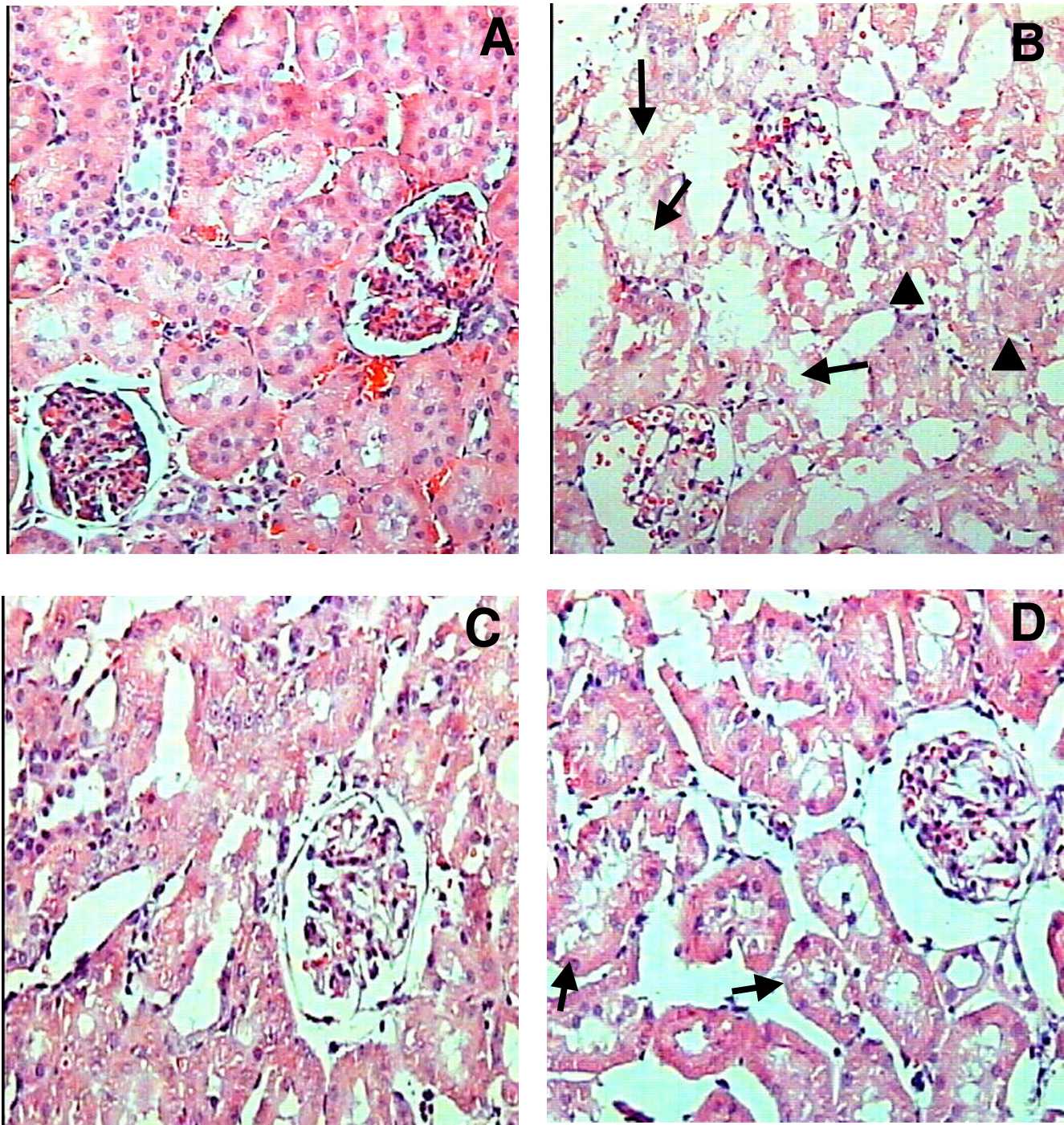


**Figure 2**  
 Urinary excretion of (A) total protein and (B) NAG on day 3 in the four groups of rats studied. Data are mean ± SEM. n = 5–6. <sup>a</sup>P < 0.001 vs. Ct, <sup>b</sup>P < 0.05 vs. Cis. Cisplatin-treated rats increased urinary excretion of total protein and NAG and these increases were prevented by FeTPPS administration in Cis+FeTPPS group.

stress is involved in this process [2,3,13,30]. The protective effect of overexpression of Mn-SOD [4] or the *in vivo* administration of some antioxidants such as vitamins C and E [5,10], melatonin [9], or selenium [31] in cisplatin-induced nephrotoxicity as well as the protective effect of tiron (a cell permeable O<sub>2</sub><sup>•</sup> scavenger), pyruvate and catalase (H<sub>2</sub>O<sub>2</sub> scavengers), and dimethylthiourea and thiourea (•OH scavengers) in renal proximal tubular epithelial cells (LLC-PK1 cells) treated with cisplatin also strongly support the role of ROS in cisplatin renal toxicity [30].

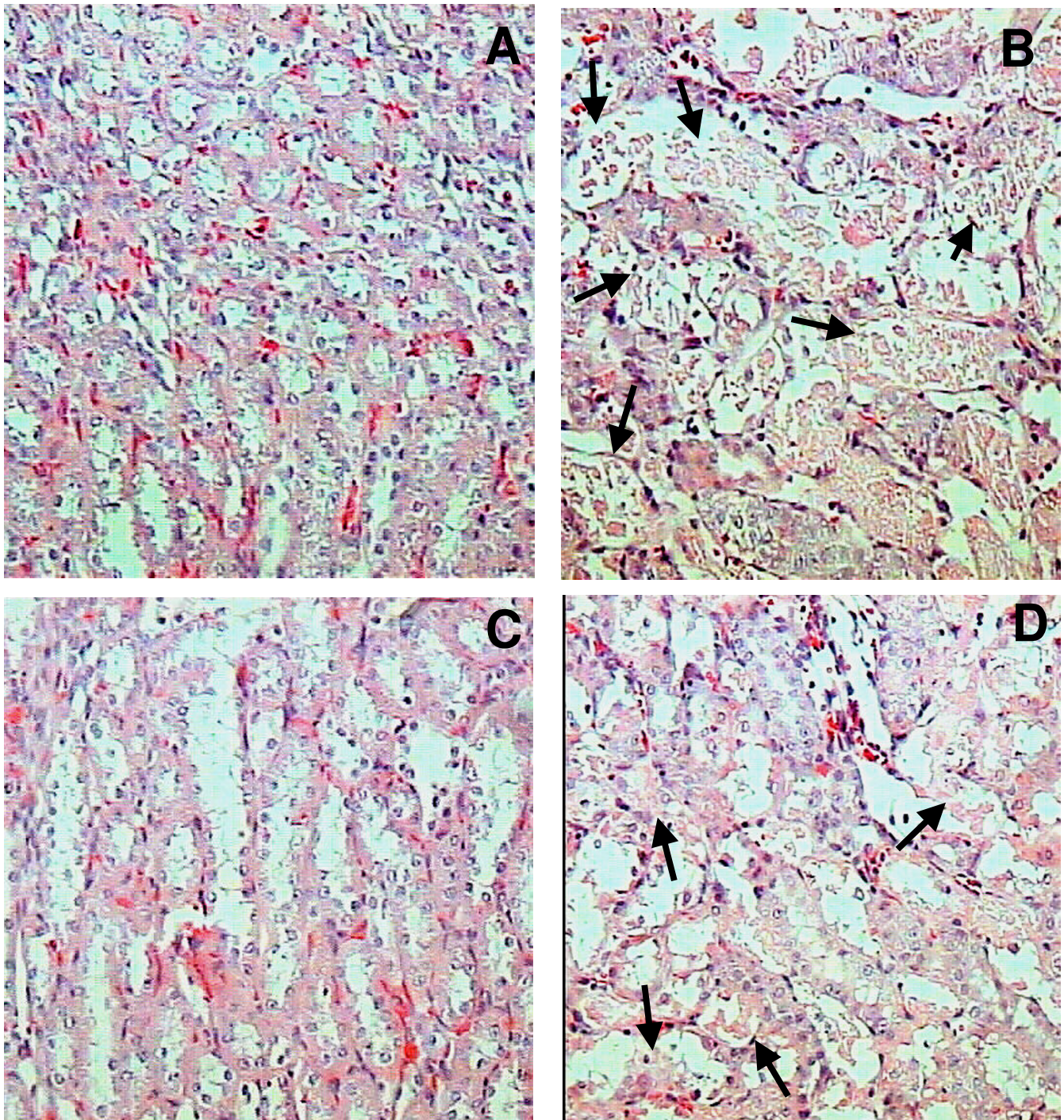
In contrast the role of •NO and RNS in cisplatin-induced nephrotoxicity has not been completely established. It has been shown that the renal content of nitrate/nitrite is increased in cisplatin-treated rats suggesting that •NO is increased in these animals [18,19]. In fact it has been shown that renal NOS activity is increased in cisplatin-treated rats [14]. In addition, the following two experiments suggest a toxic role of •NO on cisplatin-induced renal toxicity: (a) aminoguanidine, an inhibitor of inducible NOS, decreased nephrotoxicity and prevented kidney lipid peroxidation and reduction of antioxidant enzymes induced by cisplatin [13], and (b) the administration of N(G)-nitro-L-arginine methyl ester (L-NAME), an inhibitor of NOS, reduced renal and gastrointestinal toxicity along with a significant inhibition in lipid peroxidation



**Figure 3**

Representative histological abnormalities in the external cortical kidney area after three days of cisplatin administration and their partial prevention by FeTPPS. (A) Normal kidney histology from control rat. (B) After three days of cisplatin administration, many cortical convoluted tubules are revisited by necrotic epithelial cells (arrows) or vacuolated swell cells (arrow heads), glomeruli do not show apparent damage. (C) FeTPPS administration does not produce histological kidney abnormalities. (D) The administration of FeTPPS partially prevents the cytotoxic damage induced by cisplatin; arrows indicate middle cellular vacuolization of cortical convoluted tubules.

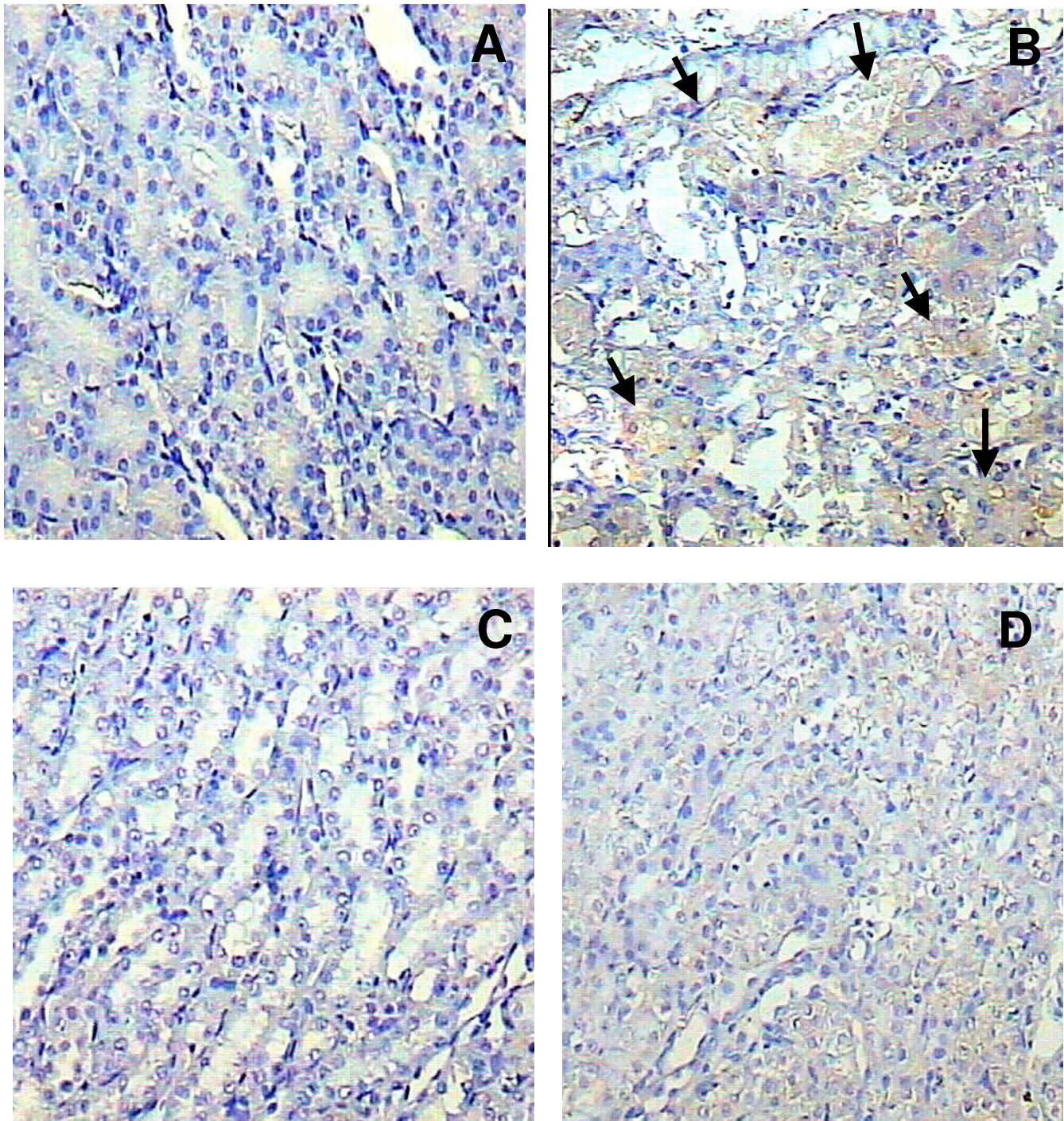




**Figure 4**

Representative histological abnormalities in the inner part of the cortical kidney after three days of cisplatin administration and their partial prevention by FeTPPS. (A) Normal kidney histology from control rat. (B) After three days of cisplatin administration, the straight portion of many cortical tubules are revisited by necrotic cells (arrows). (C) FeTPPS administration does not produce histological abnormalities. (D) The administration of FeTPPS partially prevents the cytotoxic damage induced by cisplatin; arrows indicate tubules with focal necrotic cells.



**Figure 5**

Nitrotyrosine (3-NT) expression determined by immunohistochemistry in the inner part of the cortical kidney after three days of cisplatin administration and its partial prevention by FeTPPS. (A) There is no 3-NT immunostaining in the kidney of control rat. (B) In contrast, three days after cisplatin administration there is a strong 3-NT expression in the necrotic cells from the straight portion of the proximal convoluted tubules (arrows). (C) FeTPPS administration does not induce 3-NT expression. (D) The administration of FeTPPS strongly decreases 3-NT expression induced by cisplatin-treatment (Cis+FeTPPS group).

induced by cisplatin [14]. In contrast, Mansour *et al.* [15] and Li *et al.* [16] have found that L-NAME administration resulted in no protection and Saad *et al.* [17] found that this NOS inhibitor aggravates cisplatin-induced renal dysfunction. These data may suggest that •NO is not playing a toxic role in cisplatin-induced nephrotoxicity. The above mentioned disagreement justify the performance of additional experiments to clarify the role of NOS and •NO in cisplatin-induced nephrotoxicity.

On the other hand, •NO is able to react with  $O_2^{\bullet-}$  to produce ONOO<sup>-</sup>, which is a powerful oxidant more reactive than its precursors, and has been implicated in an increasing list of diseases: hyperlipidemia [32], Alzheimer [20], acute renal ischemia [25], neurotoxicity induced by methamphetamine [33], and diabetes [23]. The ONOO<sup>-</sup> decomposition catalyst FeTPPS is a water-soluble Fe (III) porphyrin complex able to block ONOO<sup>-</sup> toxicity [28,29] and to protect against toxic insults in several experimental models. In focal cerebral ischemia-reperfusion in rats, massive production of •NO and  $O_2^{\bullet-}$  results in continuous formation of ONOO<sup>-</sup> even several hours after ischemia-reperfusion insult [34]. Significant reduction of 3-NT in brain sections and prominent neuroprotection was observed by FeTPPS (30 mg/kg) [34]. In a model of sepsis induced by injection of endotoxin (10 mg/kg) in rats, FeTPPS prevented the accumulation of ONOO<sup>-</sup> as measured by plasma rhodamine fluorescence and heart 3-NT staining [35]. Interestingly, FeTPPS improved endotoxin-induced myocardial contractile dysfunction, which was associated with reduced degradation of nuclear factor kappa B inhibitory protein I-kappa-B, plasma TNF-alpha levels, and microvascular endothelial cell-leukocyte activation [35].

In this work it was found that FeTPPS partially prevented the increase in BUN and serum creatinine (markers of glomerular damage) and urinary excretion of NAG and total protein (markers of tubular damage) induced by cisplatin-treatment. The increase in urinary NAG and total protein excretion could be associated with necrosis of the proximal convoluted tubules, the primary site of drug accumulation [1]. FeTPPS prevented these alterations induced by cisplatin. This may be secondary to the ability of FeTPPS to catalyze the decomposition of ONOO<sup>-</sup> which could be responsible, at least in part, of the alterations induced by cisplatin. This ameliorative effect of FeTPPS was associated with the decrease in 3-NT staining suggesting that ONOO<sup>-</sup> is involved in protein nitration in cisplatin-nephrotoxicity. It is known that another RNS such as  $N_2O_4$ , HONOO<sup>-</sup>, •NO<sub>2</sub> [36], and nitryl chloride (NO<sub>2</sub>Cl) [37], are involved in protein nitration. Nitryl chloride is formed by the reaction of NO<sub>2</sub><sup>-</sup> and HOCl-derived myeloperoxidase [37].

Studies in animals have established that tubular injury plays a central role in the reduction of glomerular filtration rate in acute tubular necrosis. Two major tubular abnormalities could be involved in the decrease in glomerular function in cisplatin-treated rats: obstruction and backleak of glomerular filtrate. The alteration in glomerular function can not be attributed to structural damage since glomeruli structure is normal in cisplatin-treated rats. The alterations in glomerular function in cisplatin-treated rats may also be secondary to ROS [38] which induce mesangial cells contraction, altering the filtration surface area and modifying the ultrafiltration coefficient, factors that decrease the glomerular filtration rate. In addition our data suggest that ONOO<sup>-</sup> may also be involved in the glomerular alterations in cisplatin-treated rats.

The increase in renal ONOO<sup>-</sup> induced by cisplatin may be secondary to the increase in •NO and  $O_2^{\bullet-}$  production. In fact, there are evidences of the renal increase in •NO production in cisplatin nephrotoxicity [18,19] and  $O_2^{\bullet-}$  generation in cisplatin-treated LLC-PK1 cells [30]. The  $O_2^{\bullet-}$  increase in cisplatin-nephrotoxicity may be simply consequence of the mitochondrial dysfunction [39] and the decrease in superoxide dismutase activity [5].

## Conclusions

Nitrosative stress is involved in cisplatin-induced nephrotoxicity in rats. The ameliorative effect of FeTPPS on cisplatin-induced nephrotoxicity in rats was associated with the decrease in protein nitration suggesting that ONOO<sup>-</sup> is involved in both protein nitration and nephrotoxicity in these animals.

## Methods

### Reagents

Cisplatin (catalogue # P-4394) was from Sigma-Aldrich (St. Louis MO, USA). FeTPPS (catalogue # 341492) was from (Calbiochem, San Diego, CA, USA). Rabbit anti-3-NT polyclonal antibodies (Catalogue # 06-284) were from Upstate (Lake Placid, NY, USA). Anti-rabbit Ig horseradish peroxidase antibodies (Catalogue # SAB-300) were purchased from Stressgen (Victoria BC, Canada). Commercial kits to measure creatinine and urea were from Spinreact (Girona, Spain). All other chemicals were reagent grade and commercially available.

### Experimental design

Male Wistar rats (Harlan Teklad, Mexico City, Mexico) initially weighing 200–250 g were used. Experimental work was approved by DGAPA (IN227103) and followed the guidelines of Norma Oficial Mexicana (NOM-ECOL-087-1995). All animals had free access to water and commercial rodent diet (Harlan Teklad, catalogue 2018S), and were randomly divided in four groups (n = 6 rats/group)



as follows: (1) CT, injected intraperitoneally (i.p.) with isotonic saline solution; (2) Cis, treated with a single dose of cisplatin (7.5 mg/Kg b.w./i.p.) [40]; (3) FeTPPS, treated with FeTPPS (15 mg/kg/i.p./12 h) [32] for 3 days; and (4) Cis+FeTPPS, treated with Cis and with FeTPPS. During the study rats were maintained with a 12-h light:dark cycle in stainless steel metabolic cages to collect urine. On day 3, the animals were sacrificed by decapitation and blood was collected to obtain serum and to measure creatinine and BUN. Total protein and NAG were measured in 24-h urine. The kidneys were removed to obtain cortex samples for histological and immunohistochemical studies.

#### Markers of glomerular and tubular damage

The markers of glomerular damage, creatinine and urea, were measured using commercial kits. BUN was obtained by correcting the urea value by a 2.14 factor [41]. As markers of tubular damage, we measured urinary excretion of NAG and total protein. NAG activity was measured using p-nitrophenyl-N-acetyl- $\beta$ -D-glucosaminide as substrate and total protein was measured by a turbidimetric method [42].

#### Histological analysis

Thin slices of kidney tissue with cortex and medulla were fixed by immersion in buffered formalin (pH 7.4), dehydrated and embedded in paraffin [43]. Sections of 3  $\mu$ m were stained with hematoxylin and eosin. The histological profile of twenty proximal tubules randomly selected per rat (6 rats per experimental group) was recorded using a Leica Qwin Image Analyzer (Cambridge, England). The percentage of tubular area with histopathological alterations like swelling, cytoplasmic vacuolization, desquamation or necrosis was obtained. The percentage of damaged area of Cis and Cis+FeTPPS groups was compared.

#### Immunohistochemical localization of 3-nitro-L-tyrosine (3-NT)

For immunohistochemistry, 3  $\mu$ m sections were deparaffined with xylol and rehydrated with ethanol. Endogenous peroxidase was quenched/inhibited with 4.5% H<sub>2</sub>O<sub>2</sub> in methanol by incubation for 1.5 h at room temperature. Nonspecific adsorption was minimized by leaving the sections in 3% bovine serum albumin in phosphate buffer saline for 30 min. Sections were incubated overnight with a 1:700 dilution of anti-3-NT antibody. After extensive washing with phosphate buffer saline, the sections were incubated with a 1:1000 dilution of a peroxidase conjugated anti-rabbit Ig antibody for 1 h, and finally incubated with hydrogen peroxide-diaminobenzidine for 10 s. Sections were counterstained with hematoxylin and observed under light microscopy. All the sections from the four studied groups were incubated under the same conditions with the same antibodies concentration, and in the same

running, so the immunostaining was comparable among the different experimental groups [43].

#### Statistics

Results are expressed as the mean  $\pm$  SEM. Data were analyzed by one-way ANOVA followed by Bonferroni's multiple comparisons. Non-paired t-test was used to compare the quantitative histological damage data using the software Prism 3.02 (GraphPad, San Diego, CA, USA).  $P \leq 0.05$  was considered statistically significant.

#### Authors' contributions

YICH performed animal experimentation, biochemical determinations, statistical analyses, light microscopy and immunohistochemical studies. RHP supported the light microscopy and immunohistochemical studies. JPCH conceived, designed and coordinated the study. All authors read and approved the final manuscript.

#### Acknowledgements

This work was supported by DGAPA (IN227103 and IX203504).

#### References

- Kuhlmann MK, Burkhardt G, Kohler H: **Insights into potential cellular mechanisms of cisplatin nephrotoxicity and their clinical application.** *Nephrol Dial Transplant* 1997, **12**:2478-2480.
- Inselmann G, Blomer A, Kottny W, Nellesen U, Hanel H, Heidemann HT: **Modification of cisplatin-induced renal p-aminohippurate uptake alteration and lipid peroxidation by thiols, Ginkgo biloba extract, deferoxamine and torbafylline.** *Nephron* 1995, **70**:425-429.
- Yilmaz HR, Iraz M, Sogut S, Ozyurt H, Yildirim Z, Akyol O, Gergerlioglu S: **The effects of erdoisteine on the activities of some metabolic enzymes during cisplatin-induced nephrotoxicity in rats.** *Pharmacol Res* 2004, **50**:287-290.
- Davis CA, Nick HS, Agarwal A: **Manganese superoxide dismutase attenuates Cisplatin-induced renal injury: importance of superoxide.** *J Am Soc Nephrol* 2001, **12**:2683-2690.
- Kadikoylu G, Bolaman Z, Demir S, Balkaya M, Akalin N, Enli Y: **The effects of desferrioxamine on cisplatin-induced lipid peroxidation and the activities of antioxidant enzymes in rat kidneys.** *Hum Exp Toxicol* 2004, **23**:29-34.
- Shino Y, Itoh Y, Kubota T, Yano T, Sendo T, Oishi R: **Role of poly(ADP-ribose)polymerase in cisplatin-induced injury in LLC-PKI cells.** *Free Radic Biol Med* 2003, **35**:966-977.
- Husain K, Morris C, Whitworth C, Trammell GL, Rybak LP, Somani SM: **Protection by ebselen against cisplatin-induced nephrotoxicity: antioxidant system.** *Mol Cell Biochem* 1998, **178**:127-133.
- Sueishi K, Mishima K, Makino K, Itoh Y, Tsuruya K, Hirakata H, Oishi R: **Protection by a radical scavenger edaravone against cisplatin-induced nephrotoxicity in rats.** *Eur J Pharmacol* 2002, **451**:203-208.
- Sener G, Satiroglu H, Kabasakal L, Arbak S, Oner S, Ercan F, Keyer-Uysa M: **The protective effect of melatonin on cisplatin nephrotoxicity.** *Fundam Clin Pharmacol* 2000, **14**:553-560.
- Weijl NI, Elsendoorn TJ, Lentjes EG, Hopman GD, Wipkink-Bakker A, Zwinderman AH, Cleton FJ, Osanto S: **Supplementation with antioxidant micronutrients and chemotherapy-induced toxicity in cancer patients treated with cisplatin-based chemotherapy: a randomised, double-blind, placebo-controlled study.** *Eur J Cancer* 2004, **40**:1713-1723.
- Shiraishi F, Curtis LM, Truong L, Poss K, Visner GA, Madsen K, Nick HS, Agarwal A: **Heme oxygenase-1 gene ablation or expression modulates cisplatin-induced renal tubular apoptosis.** *Am J Physiol Renal Physiol* 2000, **278**:F726-F736.
- Agarwal A, Nick HS: **Renal response to tissue injury: lessons from heme oxygenase-1 Gene ablation and expression.** *J Am Soc Nephrol* 2000, **11**:965-973.

13. Mansour MA, Mostafa AM, Nagi MN, Khattab MM, Al-Shabanah OA: **Protective effect of aminoguanidine against nephrotoxicity induced by cisplatin in normal rats.** *Comp Biochem Physiol C Toxicol Pharmacol* 2002, **132**:123-128.
14. Srivastava RC, Farookh A, Ahmad N, Misra M, Hasan SK, Husain MM: **Evidence for the involvement of nitric oxide in cisplatin-induced toxicity in rats.** *Biometals* 1996, **9**:139-142.
15. Mansour MA, Al-Shabanah OA, El-Khashef HA: **L-arginine ameliorates kidney function and urinary bladder sensitivity in experimentally-induced renal dysfunction in rats.** *J Biochem Mol Biol* 2003, **36**:373-378.
16. Li Q, Bowmer CJ, Yates MS: **The protective effect of glycine in cisplatin nephrotoxicity: inhibition with NG-nitro-L-arginine methyl ester.** *J Pharm Pharmacol* 1994, **46**:346-351.
17. Saad SY, Najjar TA, Daba MH, Al-Rikabi AC: **Inhibition of nitric oxide synthase aggravates cisplatin-induced nephrotoxicity effect of 2-amino-4-methylpyridine.** *Chemotherapy* 2002, **48**:309-315.
18. Yildirim Z, Sogut S, Odaci E, Iraz M, Ozyurt H, Kotuk M, Akyol O: **Oral erdoesteine administration attenuates cisplatin-induced renal tubular damage in rats.** *Pharmacol Res* 2003, **47**:149-156.
19. Ozen S, Akyol O, Iraz M, Sogut S, Ozugurlu F, Ozyurt H, Odaci E, Yildirim Z: **Role of caffeic acid phenethyl ester, an active component of propolis, against cisplatin-induced nephrotoxicity in rats.** *J Appl Toxicol* 2004, **24**:27-35.
20. Castegna A, Thongboonkerd V, Klein JB, Lynn B, Markesbery WR, Butterfield DA: **Proteomic identification of nitrated proteins in Alzheimer's disease brain.** *J Neurochem* 2003, **85**:1394-1401.
21. Luth HJ, Munch G, Arendt T: **Aberrant expression of NOS isoforms in Alzheimer's disease is structurally related to nitrotyrosine formation.** *Brain Res* 2002, **953**:135-143.
22. Mabley JG, Liaudet L, Pacher P, Southan GJ, Salzman AL, Szabo C: **Part II: beneficial effects of the peroxynitrite decomposition catalyst FPI5 in murine models of arthritis and colitis.** *Mol Med* 2002, **8**:581-590.
23. Szabo C, Mabley JG, Moeller SM, Shimanovich R, Pacher P, Virag L, Soriano FG, Van Duzer JH, Williams W, Salzman AL, Groves JT: **Part I: pathogenetic role of peroxynitrite in the development of diabetes and diabetic vascular complications: studies with FPI5, a novel potent peroxynitrite decomposition catalyst.** *Mol Med* 2002, **8**:571-580.
24. Yokozawa T, Rhyu DY, Cho EJ: **Protection by the Chinese prescription Wen-Pi-Tang against renal tubular LLC-PK1 cell damage induced by 3-morpholinolinosydnonimine.** *J Pharm Pharmacol* 2003, **55**:1405-1412.
25. Noiri E, Nakao A, Uchida K, Tsukahara H, Ohno M, Fujita T, Brodsky S, Goligorsky S: **Oxidative and nitrosative stress in acute renal ischemia.** *Am J Physiol Renal Physiol* 2001, **281**:F948-F957.
26. Alvarez B, Radi R: **Peroxynitrite reactivity with amino acids and proteins.** *Amino Acids* 2003, **25**:295-311.
27. Szabo C: **Multiple pathways of peroxynitrite cytotoxicity.** *Toxicol Lett* 2003, **140-141**:105-112.
28. Jensen M, Riley D: **Peroxynitrite decomposition activity of iron porphyrin complexes.** *Inorg Chem* 2002, **41**:4788-4797.
29. Misko TP, Highkin MK, Veenhuizen AV, Manning PT, Stern MK, Currie MG, Salvemini D: **Characterization of the cytoprotective action of peroxynitrite decomposition catalysts.** *J Biol Chem* 1998, **273**:15646-15653.
30. Baek SM, Kwon CH, Kim JH, Woo JS, Jung JS, Kim YK: **Differential roles of hydrogen peroxide and hydroxyl radical in cisplatin-induced cell death in renal proximal tubular epithelial cells.** *J Lab Clin Med* 2003, **142**:178-186.
31. Naziroglu M, Karaoglu A, Aksoy AO: **Selenium and high dose vitamin E administration protects cisplatin-induced oxidative damage to renal, liver and lens tissues in rats.** *Toxicology* 2004, **195**:221-230.
32. Onody A, Csonka C, Giricz Z, Ferdinandy P: **Hyperlipidemia induced by a cholesterol-rich diet leads to enhanced peroxynitrite formation in rat vessels.** *Cardiovasc Res* 2003, **58**:663-670.
33. Imam SZ, Islam F, Itzhak Y, Slikker W Jr, Ali SF: **Prevention of dopaminergic neurotoxicity by targeting nitric oxide and peroxynitrite: implications for the prevention of methamphetamine-induced neurotoxic damage.** *Ann N Y Acad Sci* 2000, **914**:157-171.
34. Thiyagarajan M, Kaul CL, Sharma SS: **Neuroprotective efficacy and therapeutic time window of peroxynitrite decomposition catalysts in focal cerebral ischemia in rats.** *Br J Pharmacol* 2004, **142**:899-911.
35. Lancel S, Tissier S, Mordon S, Marechal X, Depontieu F, Scherpereel A, Chopin C, Neviere R: **Peroxynitrite decomposition catalysts prevent myocardial dysfunction and inflammation in endotoxemic rats.** *J Am Coll Cardiol* 2004, **43**:2348-2358.
36. Eberhardt M: *Reactive oxygen metabolites: chemistry and medical consequences* Boca Raton: CRC Press LLC; 2001.
37. Eiserich JP, Hristova M, Cross CE, Jones AD, Freeman BA, Halliwell B, van der Vliet A: **Formation of nitric oxide-derived inflammatory oxidants by myeloperoxidase in neutrophils.** *Nature* 1998, **391**:393-397.
38. Duque I, Garcia-Escribano C, Rodriguez-Puyol M, Diez-Marques ML, Lopez-Novoa JM, Arribas I, Hernando L, Rodriguez-Puyol D: **Effects of reactive oxygen species on cultured rat mesangial cells and isolated rat glomeruli.** *Am J Physiol* 1992, **263**:F466-F473.
39. Kruidering M, Van de Water B, de Heer E, Mulder GJ, Nagelkerke JF: **Cisplatin-induced nephrotoxicity in porcine proximal tubular cells: mitochondrial dysfunction by inhibition of complexes I to IV of the respiratory chain.** *J Pharmacol Exp Ther* 1997, **280**:638-649.
40. Al-Majed AA, Abd-Allah AR, Al-Rikabi AC, Al-Shabanah OA, Mostafa AM: **Effect of oral administration of Arabic gum on cisplatin-induced nephrotoxicity in rats.** *J Biochem Mol Toxicol* 2003, **17**:146-153.
41. Pedraza-Chaverri J, Barrera D, Maldonado PD, Chirino YI, Macias-Ruvalcaba NA, Medina-Campos ON, Castro L, Salcedo MI, Hernandez-Pando R: **S-allylmercaptocysteine scavenges hydroxyl radical and singlet oxygen in vitro and attenuates gentamicin-induced oxidative and nitrosative stress and renal damage in vivo.** *BMC Clin Pharmacol* 2004, **4**:5.
42. Maldonado PD, Barrera D, Rivero I, Mata R, Medina-Campos ON, Hernandez-Pando R, Pedraza-Chaverri J: **Antioxidant S-allyl-cysteine prevents gentamicin-induced oxidative stress and renal damage.** *Free Radic Biol Med* 2003, **35**:317-324.
43. Barrera D, Maldonado PD, Medina-Campos ON, Hernandez-Pando R, Ibarra-Rubio ME, Pedraza-Chaverri J: **HO-1 induction attenuates renal damage and oxidative stress induced by K2Cr2O7.** *Free Radic Biol Med* 2003, **34**:1390-1398.

Publish with **BioMed Central** and every scientist can read your work free of charge

"BioMed Central will be the most significant development for disseminating the results of biomedical research in our lifetime."

Sir Paul Nurse, Cancer Research UK

Your research papers will be:

- available free of charge to the entire biomedical community
- peer reviewed and published immediately upon acceptance
- cited in PubMed and archived on PubMed Central
- yours — you keep the copyright

Submit your manuscript here:  
[http://www.biomedcentral.com/info/publishing\\_adv.asp](http://www.biomedcentral.com/info/publishing_adv.asp)

